

Nephroprotective Property of Ethanolic Extract of *Moringa Oleifera* Bark against Gentamicin Induced Nephrotoxicity in Wistar Rats

Shrishail K Nimbale,¹ Hasanpasha N Sholapur,^{2*} Savardekar Rohan Ram,¹ Neelakanth M Jeedi,¹ Vineeta Nagathan,³ Fatima Sanjeri Dasankoppa.³

¹ Department of Pharmacology, KLE College of Pharmacy, Hubballi -580 031, India

² Department of Pharmacognosy, KLE College of Pharmacy, Hubballi -580 031, India

³ Department of Pharmaceutics, KLE College of Pharmacy, Hubballi -580 031, India

Abstract

Gentamicin is reported to cause acute renal failure in 20% of hospitalized patients due to oxidative stress on the proximal tubule of kidneys. *Moringa oleifera* (MO) bark is reported to contain a high concentration of antioxidants. Hence this study aimed to evaluate the nephroprotective effect of *Moringa oleifera* bark against gentamicin-induced nephrotoxicity. Ethanolic extract of *Moringa oleifera* bark was studied for its nephroprotective effect in experimental rat models. Nephrotoxicity was induced by Gentamicin by administering 80mg/kg for 8 days *i.p.* MO bark extract at doses of 250 mg/kg and 125mg/kg was evaluated for nephro-protective properties. The nephroprotective action was evaluated by blood serum parameters such as Creatine, Urea, Total protein, Uric acid, LDH, and tissue parameters such as MDA, GSH, LPO, and SOD followed by histopathology studies of the kidney. Gentamicin-treated rats exhibited, elevated levels of blood serum creatine, total protein, LDH, uric acid, urea, and LPO, and a decrease in antioxidants such as SOD, catalase, and GSH compared to the control group. Treatment with a high dose (250mg/kg) and low dose (125mg/kg) of extract of *Moringa oleifera* bark shows a significant decrease in the levels of blood serum creatine, total protein, LDH, uric acid, urea, and LPO and increase in the levels of antioxidants such as SOD, catalase, GSH compared to gentamicin group. In addition, gentamicin led to cellular damages including peritubular congestion, epithelial desquamation, blood vessel congestion, and necrosis, all of which were partially recovered by *Moringa oleifera* bark extract.

Key Words-Gentamicin, nephrotoxicity, nephroprotective, *Moringa oleifera*, rats.

1. Introduction

Nephrotoxicity is diminished kidney function due to the administration of various toxic medications and chemicals [1]. Around 20% of nephrotoxicity is caused by medications, leading to changes in the blood flow to the kidneys, damage to nephrons, and allergic reactions [2]. Acute renal failure and chronic renal failure are the two broad types of kidney failure. Annually around 37 million people in the US suffer from chronic kidney diseases (CKD) persuaded by diabetes and high blood pressure [3] other causes of CKD are glomerulonephritis [4] polycystic kidney disease [5], lupus nephritis [6], kidney cancer [7]. Other causes are related to the use of medications such as amphotericin B [8,9], NSAIDs [10], gentamicin (GM) [11,12], calcineurin inhibitors [13], and aminoglycosides. Medications-induced nephrotoxicity can be prevented by including additional

nephroprotective agents as part of the treatment regimen [14, 15]. Plants have proven to be the best source, offering nephroprotective compounds that can act at various stages of the physiological pathways. Plants offer a wide range of traditional medical applications as well as anti-inflammatory, diuretic, antioxidant, and anti-cancer qualities [16]. *Moringa oleifera* bark commonly known as a drum stick belonging to the family Moringaceae [17]. Traditionally is used to cure diseases like kidney stones, hypertension, thyroid problems, skin diseases, anti-inflammatory and also in diabetes [18,19]. Almost all parts of *Moringa oleifera* can be used as a source of nutrition [20,21]. *Moringa* species contain various phytoconstituents such as saponins, tannins, steroids, phenolic acids, glycosylates, flavonoids, and terpenes [22].

Traditionally it has been reported for various uses such as a diuretic, expectorant, stimulant, and antispasmodic [23]. However, there is a lack of scientific reports regarding the effect of the bark of *Moringa oleifera lam* on nephroprotective. Hence this study aimed to evaluate the nephroprotective effect of *Moringa oleifera* bark extract against gentamicin induced nephrotoxicity.

2. Materials And Methods

The study was performed as per CCSEA (Committee for Control and supervision of Experiments on Animals) guidelines. The study was commenced after IAEC (Institutional Animal Ethics Committee) approval.

2.1 Plant material and drug preparation

Moringa oleifera lam. bark was collected and authenticated by a botanist. A voucher specimen is maintained in the department. The bark was washed with water, shade-dried, and powdered with a mechanical grinder. To obtain a consistent, coarse powder of a 40 mesh size. The dried bark powder 250g was extracted by maceration using 3 X 1 L of ethanol 80% v/v in a closed glass container for 24 h, initially shaking it constantly for the first 6 hours, then letting it stand for the following 18h. The extract obtained was quickly filtered under vacuum using Whatmann filter paper no. 1. The residue was further macerated twice similarly. The filtrates obtained above were concentrated in a rota evaporator below 40°C under vacuum. Finally, the concentrated extract was desiccated dried, weighed, and kept in a sterile container at a temperature of 4 to 8 °C until further use [24].

2.2 Experimental animal

Adult albino rats of either sex weighing about 180-250g were used. Animals were housed in cages at room temperature (27⁰±1). under 12-hour light & dark cycles with food & water. All animal experiments were performed after the approval of the institutional animal ethical committee bearing proposal no. (06/KLECOPH/21).

2.3 Dose selection of extract

The dose selection of alcoholic extract of *Moringa oleifera.* bark (250mg/kg) used in present study was based on earlier study reported on this plant in diabetic study [25].

2.4 Gentamicin induced nephrotoxicity

Injection of gentamicin was obtained from the registered retailer. Rats were separated into four groups of six rats (n=6) in each group,

Group I as control given normal saline orally at 1ml/kg body weight for daily 8 days.

Group II rats were treated with gentamicin (80mg/kg body weight) *i.p.* injection for 8 days [26,27]. Group III and IV were treated similarly to group II along with ethanolic extract of *Moringa oleifera bark* at a dose of 125mg/kg (LDMO) and 250mg/kg (HDMO) of body weight for 8 days respectively.

2.5 Assessment of physical and biochemical parameter

After the last dose, a blood sample was collected by retro-orbital puncture under light ether anesthesia to estimate the uric acid, creatinine, blood urea nitrogen [28], total protein [29], and LDH [30]. Changes in body weight and kidney weight were also measured.

2.6 Assessment of Renal oxidative stress and Anti-oxidant parameter

Under deep anesthesia, all the animals were sacrificed and the kidney was removed and homogenized in saline (phosphate buffer) to measure glutathione peroxidase (GSH), catalase (CAT), superoxide dismutase (SOD) and lipid peroxidation (MDA). Ellman method was used for the determination of GSH [31], the Sinha method was used for Catalase (CAT) [32], Kakkar et al method was used for the estimation of SOD [33], and Buege and Aust's method was used for MDA assay by TBARS (thiobarbituric acid reactive species) [34].

2.7 Histopathological studies

After sacrificing the rats, kidney was isolated and washed using saline, made into small pieces and by using 10% neutral formalin solution tissues were preserved followed by washing with water and alcohol for dehydration. Later they were cleaned using xylene twice for fifteen to twenty minutes, then subjected to paraffin infiltration in an automatic tissue processing unit.

We took square-shaped blocks, which poured melted hard paraffin followed by dropping kidney pieces quickly and allowing them to cool. Tissues were cut into 5μ thicknesses by using microtome to make sections. For staining the sections, eosin and hematoxylin were used and observed for changes in histopathological characteristics by microscope [35].

2.8 Statistical analysis

One-way analysis of variance (ANOVA) was used for experimental data to know the significant levels followed by Tukey's multiple comparison test using the software Graph Pad Prism 5.0. Data were stated as Mean \pm S.E.M and differences were considered significant at $p < 0.05$ [36].

3. Results

The effect of a high dose of ethanolic extract of *Moringa oleifera* bark (250 mg/kg) and low dose of ethanolic extract of *Moringa oleifera* bark (125mg/kg) was studied for the effect on kidney weight by gentamicin intoxication. Renal injury caused by gentamicin significantly increased ($p < 0.001$) compared to the control group. Nephroprotective in terms of reduced mean kidney weight post-intoxication was observed at a maximum dose of 250mg/kg when compared gentamicin group.

The gentamicin-treated group showed a significant reduction in body weight ($p < 0.001$) reduction in body weight compared to normal group. However, in the treatment group of high doses of *Moringa oleifera* bark showed a significant increase in body weight ($p < 0.001$), and low doses of *Moringa oleifera* bark $p < 0.01$.

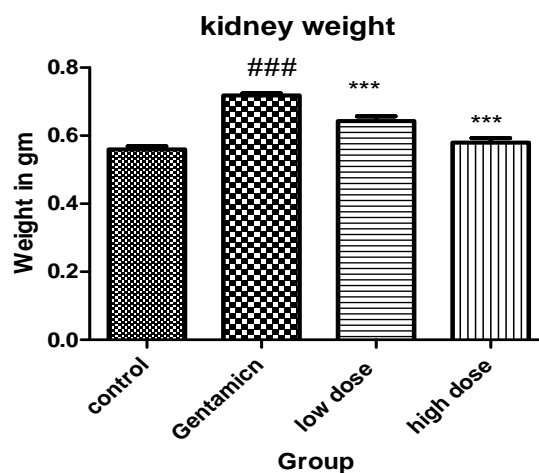


Figure 1. Effect of extract of *Moringa oleifera* bark on kidney weight in gentamicin induced nephrotoxicity

Values are Mean ± SEM; (N=6): examined by one way ANOVA followed by Tukey’s Multiple Comparison Test, whereas ^{###} $p < 0.001$ compared to control, ^{**} $p < 0.01$, ^{***} $p < 0.001$ compared to gentamicin group.

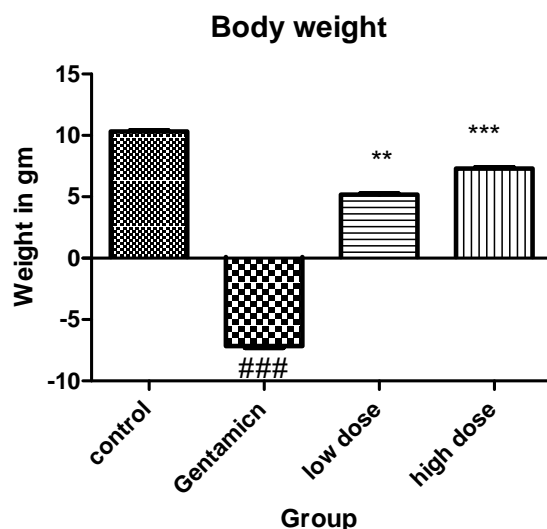


Figure 2. Effect of extract of *Moringa oleifera* bark on body weight in gentamicin induced nephrotoxicity

Values are Mean ± SEM; (N=6): examined by one way ANOVA followed by Tukey’s Multiple Comparison Test, whereas ^{###} $p < 0.001$ compared to control, ^{**} $p < 0.01$, ^{***} $p < 0.001$ compared to gentamicin group.

3.1 Assessment of serum biochemical parameters

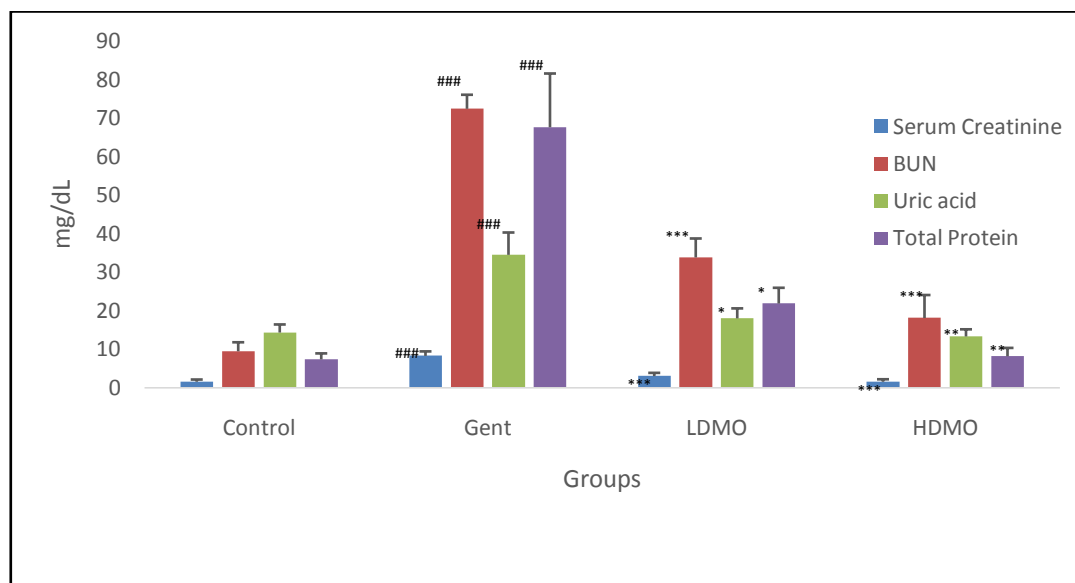


Fig. 3. Effect extract of *Moringa oleifera* bark on serum parameters

Values are Mean ± SEM; (N=6), ^{###} $p < 0.001$ when compared to control, ^{*} $p < 0.05$, ^{**} $p < 0.01$ and ^{***} $p < 0.001$ when compared to gentamicin group.

Gent – Gentamicin

LDMO – Low dose of *Moringa oleifera* extract

HDMO - High dose of *Moringa oleifera* extract

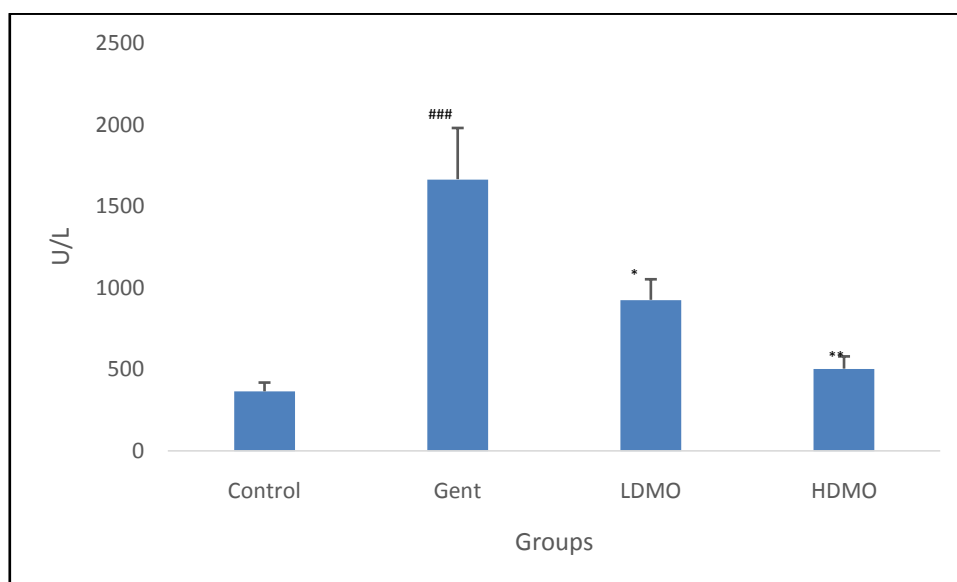


Fig. 4. Effect *Moringa Oleifera* bark extract on LDH

Values are Mean \pm SEM; (N=6), ### p <0.001 when compared to control, * p <0.05, ** p <0.01 and *** p <0.001 when compared to gentamicin group.

Gent – Gentamicin

LDMO – Low dose of *Moringa oleifera* extract

HDMO - High dose of *Moringa oleifera* extract

Figure 3 and 4 Shows blood serum parameters such as creatine, BUN, uric acid, total protein and LDH were significantly altered in the gentamicin-intoxicated group when compared to the control. However, in treatment group, high dose of extract MO (250mg/kg) and low dose of extract MO (125mg/kg) showed significant reduction in level of creatine (p <0.001 and p <0.001), BUN (p <0.001 and p <0.001), uric acid (p <0.01 and p <0.05), total protein (p <0.01 and p <0.05) and LDH (p <.001 and p <0.05) respectively.

3.2 Assessment of Anti-oxidant Parameters

Table 3:Effect of extract of *Moringa oleifera* bark on tissue parameters

Treatment Groups	CAT nmoles/mg	SOD units/ml	GSH μ L/mg	LPO μ moles/l
Control	3.36 \pm 0.12	13..91 \pm 0.02	2.542 \pm 0.00	1.488 \pm 0.29
Gentamicin	1.45 \pm 0.12	3..8702 \pm 0.02###	0.7457 \pm 0.06###	4.752 \pm 5.01###
LDMO (125 mg/kg)	1.93 \pm 0.05	7.210 \pm 0.02*	1.72715 \pm 2.01***	3.103 \pm 5.02**
HDMO (250 mg/kg)	2.230 \pm 0.11	10..683 \pm 0.02**	1.7323 \pm 1.49***	1.988 \pm 1.50***

Values are Mean \pm SEM; (N=6), ### p <0.001 when compared to control, * p <0.05, ** p <0.01 and *** p <0.001 when compared to gentamicin group.

Gentamicin-treated rats showed a decrease in SOD (p <0.001), CAT (p <0.001), and GSH (p <0.001), and an increase in LPO levels (p <0.001) in kidney tissue as compared with the control group, but pretreatment groups i.e. low dose of an extract of MO and high dose of an extract of MO and increase in the levels of SOD (p <0.01 and p <0.001), CAT (p <0.01 and p <0.001) and GSH (p <0.05 and p <0.01) and decreased levels of LPO (p <0.01 and p <0.001) respectively as compared to gentamicin group.

3.3 Histopathological Examination

Table 4: Report of histopathological examination of renal tissue.

Microscopy	Control	Gentamicin treated	LDMO	HDMO
Glomerular congestion	N	+++	++	+
Peritubular congestion	N	+++	++	++
Epithelial desquamation	N	+++	++	N
Blood vessel congestion	N	+++	++	++
Inflammatory cells	N	+++	+++	N
Necrosis	N	+++	++	N
Tubular casts	N	+++	++	N

N – Nil, ++ - Moderate, +++ - Severe

All histopathological changes were examined by the by pathologist who were ignorant of the treatment group. Gentamicin-treated rat renal tissue exhibited various changes such as glomerular congestion, peritubular congestion, epithelial desquamation, blood vessel congestion, tubular cast, and necrosis. Whereas normal rats showed normal morphological looks pretreated groups i.e. LDMO and HDMO showed less inflammation and minimal tubule damage as compared to gentamicin treated group. They were assessed with a score N- Nil, + mild, ++ moderate, and +++ severe.

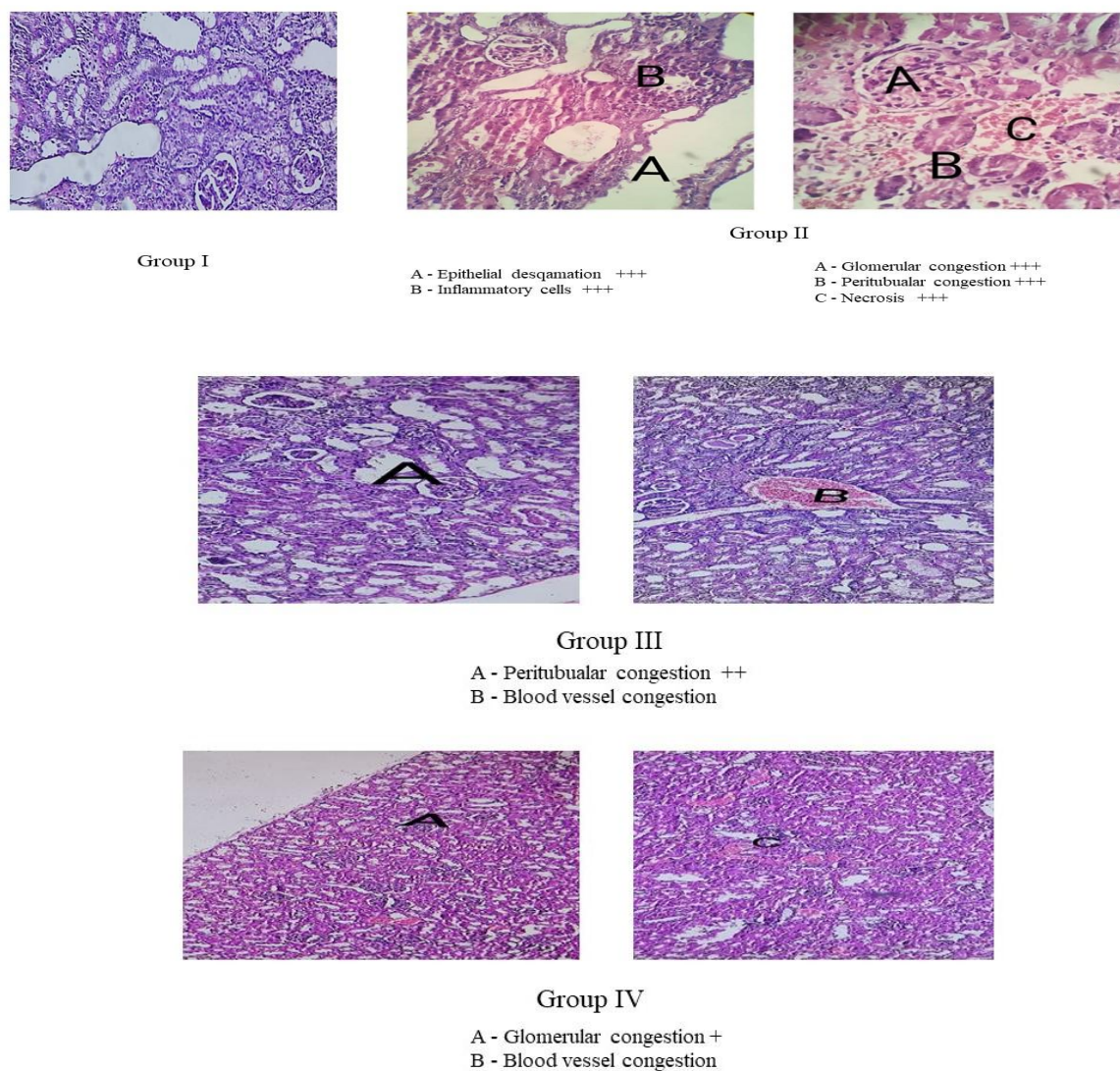


Fig 5. Histopathologic alterations in rat kidneys following gentamicin administration and the effect of *Moringa oleifera* bark extract on them in (Group I) Control (Group II) Gentamicin alone (Group III) Gentamicin + low dose of *Moringa oleifera* bark extract (Group IV) Gentamicin + high dose of *Moringa Oleifera* bark extract. (Haematoxylin and eosin, 400x)

4. Discussion

In this study, extract of *Moringa oleifera* bark attenuates the effects of gentamicin-induced nephrotoxicity as showed by decreasing kidney weight, serum creatinine, blood urea nitrogen, LDH level, total proteins, and kidney MDA, in addition to improving histopathological changes in rat's kidney tissue.

Among the aminoglycoside antibiotics, gentamicin is a widely used drug of choice for the treatment of various infections. However, nephrotoxicity and ototoxicity are the side effects of all aminoglycosides, especially gentamicin and this reduces its therapeutic usage.

In the present study, gentamicin was administered for 8 days, which resulted in a significant reduction in the body weight of rats and a significant increase in the kidney weight compared to control rats. The reduction in body weight may be due to direct injury to renal tubules resulting in the incapability of the tubular cells to

reabsorb water leading to dehydration and loss of body weight or increased catabolism [37], which finally results in anorexia, acidosis, and reduction in food intake [38]. Inflammation and edema are also responsible for the increase in kidney weight after gentamicin injection [39]. These changes were aligned with previous studies [40, 41]. Administration of ethanolic extract of *Moringa oleifera* bark significantly decreased the weight of the kidney, compared to the gentamicin-treated rats. This might be due to the anti-inflammatory effect of the extract by reducing TNF- α , IL-1, and IL-6, which are considered inflammatory cytokines [42].

Nephrotoxicity induced by Gentamicin was accompanied by a significant increase in serum creatinine, blood urea nitrogen, and protein levels. In renal dysfunction and reduced glomerular filtration rate, there is a decrease in the kidney's capacity to filter creatinine and, an increase in urea and uric acid levels [43] along with protein levels. These elevated biochemical levels are profound indicators of tubular damage, decreased resorptive capability of tubular protein, or reduced protein filtration [44].

The results of present study showed that nephrotoxicity was produced after *i.p* administration of gentamicin in rats, which was revealed by elevated serum urea and creatinine levels indicating glomerular damage. These results are coordinated with other studies [45,46]. Ethanolic extract of *Moringa oleifera* bark produced a significant reduction in serum creatinine and blood urea nitrogen levels. The improved effect on the kidney markers might be credited to the protection against oxidative injury.

Also, gentamicin is involved in inflammatory responses of renal tissue in rats [47-49], indicated by elevated serum LDH and total protein, these results are in alignment with earlier studies [50]. Treatment of rats with ethanolic extract of *Moringa oleifera* bark reduced the elevation of serum LDH induced by gentamicin, this might be due to the anti-inflammatory properties of *Moringa oleifera* bark. Oxidative stress is another mechanism of gentamicin-induced nephrotoxicity. Renal toxicity of gentamicin is by the production of reactive oxygen species in the kidney such as hydrogen peroxide, superoxide anions, and hydroxyl radicals [51, 52]. Interaction of excessively produced reactive oxygen species with cell components, such as lipids, proteins, carbohydrates, and nucleic acids resulted in damage to the cell and tissue [53]. Gentamicin-induced tissue damage might be due to the diminution of renal GSH which permits lipid peroxidation [54]. Therefore, reactive oxygen species scavengers and antioxidant molecules can partially reduce or eliminate the harmful effects induced by gentamicin.

In the present study, oxidative stress is also the cause of renal damage in gentamicin-induced nephrotoxicity. This was supported by a significant rise in the levels of malondialdehyde in renal tissue as reflected by an increase in TBARS (lipid peroxidation end product), whereas antioxidant enzymes of the kidney such as SOD, CAT, and GSH levels were reduced in the kidney tissue. These results agree with earlier studies [55].

The histological examination of kidneys in gentamicin-injected rats, showed glomerular congestion, severe peritubular congestion, severe epithelial desquamation, and severe necrosis and inflammatory cells. In animals treated with ethanolic extract of *Moringa oleifera* bark, these glomerular congestions, peritubular congestion, and necrosis was reduced, establishing its protective effect against tissue damage induced by gentamicin.

5. Conclusion

In conclusion, gentamicin-induced nephrotoxicity was protected by ethanolic extract of *Moringa oleifera* bark in rats by utilizing antioxidant and anti-inflammatory properties. Biochemical parameter measurements and histopathological examination reinforced this. Therefore, ethanolic extract of *Moringa oleifera* bark signifies a new therapy for gentamicin-induced nephrotoxicity. However, further elucidation of the cellular and molecular mechanisms would provide robust evidence for the nephroprotective effects of the extract.

6. References

- [1] Al-Naimi MS, Rasheed HA, Hussien NR, Al-Kuraishy HM, Al-Gareeb AI. Nephrotoxicity: Role and significance of renal biomarkers in the early detection of acute renal injury. *J Adv Pharm Technol Res.* 2019;10(3):95-99.

- [2] Kim SY, Moon A. Drug-induced nephrotoxicity and its biomarkers. *Biomol Ther (Seoul)*. 2012; 20(3): 268-72.
- [3] hhs.gov [Internet]. US Department of Health and Human Services. Centers for Disease Control and Prevention. Chronic Kidney Disease in the United States, 2021. [cited 2002 Aug 20]. Available from <https://www.hhs.gov/about/budget/fy-2021-cdc-contingency-staffing-plan/index.html>.
- [4] Couser WG. Glomerulonephritis. *The Lancet*. 1999;353 (9163):1509-15.
- [5] Alan SL, Shen C, Landsittel DP, Harris PC, Torres VE, Mrug M, et al. Baseline total kidney volume and the rate of kidney growth are associated with chronic kidney disease progression in Autosomal Dominant Polycystic Kidney Disease. *Kidney Int*. 2018; 93(3): 691-99.
- [6] Almaani S, Meara A, Rovin BH. Update on lupus nephritis. *Clin J Am Soc Nephrol*. 2017; 12(5): 825-35.
- [7] Porta C, Cosmai L, Leibovich BC, Powles T, Gallieni M, Bex A. The adjuvant treatment of kidney cancer: a multidisciplinary outlook. *Nat Rev Nephrol*. 2019; 15(7): 423-33.
- [8] Fanos V, Cataldi L. Amphotericin B-induced nephrotoxicity: a review. *J chemother*. 2000;12(6):463-70.
- [9] Sawaya BP, Briggs JP, Schnermann J. Amphotericin B nephrotoxicity: the adverse consequences of altered membrane properties. *J Am Soc Nephrol*. 1995; 6(2): 154-64.
- [10] .Whelton A. Nephrotoxicity of nonsteroidal anti-inflammatory drugs: physiologic foundations and clinical implications. *Am J Med*. 1999 May 31;106(5B):13S-24S.
- [11] Wargo KA, Edwards JD. Aminoglycoside-induced nephrotoxicity. *J Pharm Pract*. 2014; 27(6):573-77.
- [12] Oliveira JFP, Silva CA, Barbieri CD, Oliveira GM, Zanetta DMT, Burdmann EA. Prevalence and Risk Factors for Aminoglycoside Nephrotoxicity in Intensive Care Units. *Antimicrob Agents Chemother*. 2009; 53(7):2887-91.
- [13] Naesens M, Kuypers DRJ, Sarwal M. Calcineurin inhibitor nephrotoxicity. *Clin J Am Soc Nephrol*. 2009; 4(2):481-508.
- [14] Raza Z, Naureen Z. Melatonin ameliorates the drug induced nephrotoxicity: Molecular insights. *Nefrologia*. 2020; 40(1):12-25.
- [15] Mingeot-Leclercq MP, Tulkens PM. Aminoglycosides: nephrotoxicity. *Antimicrobial agents and chemotherapy*. 1999; 43(5):1003-12.
- [16] Tienda-Vázquez MA, Morreeuw ZP, Sosa-Hernández JE, Cardador-Martínez A, Sabath E, Melchor-Martínez EM, et al. Nephroprotective Plants: A Review on the Use in Pre-Renal and Post-Renal Diseases. *Plants*. 2022; 11(6):818.
- [17] . J Vélez-Gavilán. *Moringa oleifera* (horse radish tree). *CABI Compendium* [internet]. 2014 [cited 2014 Oct 22]. Available from: <http://www.cabi.org/isc/datasheet/34868>. Oxon, UK: CAB International 2014 [updated 13.07.2022 cited 19.08.2022).
- [18] Chopra RN NS, Chopra IC. *Glossary of Indian medicinal plants*. New Delhi, India: Council of scientific and industrial research; 1956.
- [19] Anwar F, Latif S, Ashraf M, Gilani AH. *Moringa oleifera*: A Food Plant with Multiple Medicinal Uses. *Phytother Res*. 2007;21(1):17-25.
- [20] Abdull Razis AF, Ibrahim MD, Kntayya SB. Health benefits of *Moringa oleifera*. *Asian Pac J Cancer Prev*. 2014;15(20):8571-76.
- [21] .Abd Rani NZ, Husain K, Kumolosasi E. *Moringa* genus: a review of phytochemistry and pharmacology. *Frontiers in Pharmacology*. 2018; 9:108.
- [22] .C.P. Khare. *Indian medicinal plants*. New Delhi, India: Springer; 2007, p.422-23.
- [23] .Bosch CH. *Moringa stenopetala* (Baker f.) Cufod. *Prota*. 2004;2:395-7.
- [24] Sholapur HN, Patil BM. Effect of *Moringa oleifera* bark extracts on dexamethasone-induced insulin resistance in rats. *Drug Res*. 2013; 63(10):527-31.
- [25] Kar A, Choudhary BK, Bandyopadhyay NG. Comparattive evaluation of hypoglycemic activity of some Indian medicinal plant in alloxan diabetic rats. *J Ethanopharmacol*. 2003; 84(1):105-08

- [26] Maya NA, Dewan JF, Rashid N, Sharmin K, Uddin MA, Sharmin F. Morphological Effect of Ethanol Extract of *Tinospora cordifolia* on Gentamicin-induced Nephrotoxicity in Rats. *Mymensingh Med J*. 2020; 29(4):871-78.
- [27] Alam Q, Vijayanarayana K, Nephroprotective effect of alcoholic extracts of fruits of *solanum xanthocarpum* against cisplatin induced nephropathy in rats. *Int J Adv pharm bio chem*. 2013; 2 (1); 147-51.
- [28] Walker HK, Hall WD, Hurst JW, editors. *Clinical Methods: The History, Physical, and Laboratory Examinations*. 3rd ed. Boston: Butterworths; 1990.
- [29] Dieterle F, Perentes E, Cordier A, Roth DR, Verdes P, Grenet O, et al. Urinary clusterin, cystatin C, β 2-microglobulin and total protein as markers to detect drug-induced kidney injury. *Nat Biotechnol*. 2010; 28(5); 463–69.
- [30] Farhana A, Lappin SL. *Biochemistry, Lactate Dehydrogenase*. 2023. In: *StatPearls* [Internet]. Treasure Island (FL): StatPearls Publishing; 2023.
- [31] Ellman GL. Tissue sulfhydryl groups. *Arch Biochem Biophys*. 1959;82(1):70-77.
- [32] Sinha AK. Colorimetric assay of catalase. *Anal Biochem*. 1972; 47(2):389-94.
- [33] Kakkar P, Das B, Viswanathan PN. A modified spectrophotometric assay of superoxide dismutase. *Indian J Biochem Biophys*. 1984;21(2):130-42.
- [34] Niehaus WG, Samuelsson B. Formation of malondialdehyde from phospholipids arachidonate during
- [35] Agadihiremath VS, Sumeet G, Agadihiremath T, Basavaraj CK, Donnahalli VM. Cardioprotective effect of curcumin against doxorubicin-induced myocardial toxicity in albino rats. *Indian J Pharmacol*. 2012;44(1):73–77.
- [36] Sholapur HN, Patil BM. Effect of Fractions of Alcoholic Extract of *Moringa oleifera* lam., Bark on Dexamethasone induced Insulin Resistance in Rats. *J Young Pharma* 2017; 9(3): 410-16.
- [37] Ali BH, Al-Qarawi AA, Haroun EM, Mousa HM. The effect of treatment with gum Arabic on gentamicin nephrotoxicity in rats: a preliminary study. *Ren Fail*. 2003; 25(1): 15–20.
- [38] Ali BH, Abdel Gayoum AA and Bashir AA. Gentamicin nephrotoxicity in rat: some biochemical correlates. *Pharmacol Toxicol*. 1992; 70(6 Pt 1): 419–23
- [39] Erdem A, Gundogan NU, Usubutun A, Kiling K, Erdem SR, Kara A, et al. The protective effect of taurine against gentamicin-induced acute tubular necrosis in rats. *Nephrol Dial Transplant*. 2000; 15(8): 1175–82.
- [40] El-Kashef DH, El-Kenawi AE, Rahim MA, Suddek GM, Salem HA. Agmatine improves renal function in gentamicin-induced nephrotoxicity in rats. *Can J Physiol Pharmacol*. 2016; 94(3): 278–86.
- [41] Nasri H, Nematbakhsh M, Ghobadi S, Ansari R, Shahinfard N, Rafieian-Kopaei M. Preventive and curative effects of ginger extract against histopathologic changes of gentamicin-induced tubular toxicity in rats. *Int J Prev Med*. 2013; 4(3): 316–21.
- [42] Kim SY, Moon KA, Jo HY, Jeong S, Seon SH, Jung E, et al. Anti-inflammatory effects of apocynin, an inhibitor of NADPH oxidase, in airway inflammation. *Immunol Cell Biol*. 2012; 90(4): 441–448.
- [43] Perrone RD, Madias NE, Levey AS. Serum creatinine as an index of renal function: new insights into old concepts. *Clin Chem*. 1992; 38(10): 1933–53.
- [44] Mueller PW, Lash LH, Price RG, Stolte H, Gelpi E, Maack T, et al. Urinary biomarkers to detect significant effects of environmental and occupational exposure to nephrotoxins. I. Categories of tests for detecting effects of nephrotoxins. *Ren Fail*. 1997; 19(4): 505–21.
- [45] Hosaka EM, Santos OF, Seguro AC, Vattimo MF. Effect of cyclooxygenase inhibitors on gentamicin-induced nephrotoxicity in rats. *Braz J Med Biol Res*. 2004; 37(7): 979–85.
- [46] Soliman KM, Abdul-Hamid M, Othman AI. Effect of carnosine on gentamicin-induced nephrotoxicity. *Med Sci Monit*. 2007; 13(3): BR73–BR83.
- [47] Bledsoe G, Crickman S, Mao J, Xia CF, Murakami H, Chao L, et al. Kallikrein/kinin protects against gentamicin-induced nephrotoxicity by inhibition of inflammation and apoptosis. *Nephrol Dial Transplant*. 2006; 21(3): 624–33.

- [48] Geleilete TJ, Melo GC, Costa RS, Volpini RA, Soares TJ, Coimbra TM. Role of myofibroblasts, macrophages, transforming growth factor-beta endothelin, angiotensin-II, and fibronectin in the progression of tubulointerstitial nephritis induced by gentamicin. *J Nephrol.* 2002; 15: 633–42.
- [49] Quiros Y, Vicente-Vicente L, Morales AI, López-Novoa JM, López-Hernández FJ. An integrative overview on the mechanisms underlying the renal tubular cytotoxicity of gentamicin. *Toxicol Sci.* 2011; 119 (2): 245–
- [50] El-Kashef DH, El-Kenawi AE, Suddek GM, Salem HA. Flavocoxid attenuates gentamicin-induced nephrotoxicity in rats. *Naunyn Schmiedebergs Arch Pharmacol.* 2015; 388(12):1305–15.
- [51] Yaman I and Balikci E. Protective effects of nigella sativa against gentamicin-induced nephrotoxicity in rats. *Exp Toxicol Pathol.* 2010; 62(2): 183–90.
- [52] Balakumar P, Chakkarwar VA, Kumar V, Jain A, Reddy J, Singh M. Experimental models for nephropathy. *J*
- [53] Gutteridge JM. Lipid peroxidation and antioxidants as biomarkers of tissue damage. *Clin Chem.* 1995; 41(12): 1819–28.
- [54] Manikandan R, Beulaja M, Thiagarajan R, Priyadarsini A, Saravanan R, Arumugam M. Ameliorative effects of curcumin against renal injuries mediated by inducible nitric oxide synthase and nuclear factor kappa B during gentamicin-induced toxicity in Wistar rats. *Eur J Pharmacol.* 2011; 670 (2-3): 578–85.
- [55] Aygun FO, Akcam FZ, Kaya O, Ceyhan BM, Sütçü R. Caffeic acid phenethyl ester modulates gentamicin-induced oxidative nephrotoxicity in kidney of rats. *Biol Trace Elem Res.* 2012; 145 (2): 211–16.